

# Hyperammonemic Encephalopathy and Lipid Dysmetabolism in a Critically Ill Patient after A Short Course of Amiodarone

Maximilien Cappe<sup>1</sup>, Philippe Hantson<sup>1</sup>, Mina Komuta<sup>2</sup>, Marie-Françoise Vincent<sup>3</sup>, Pierre-François Laterre<sup>1</sup>, Ismail Ould-Nana<sup>1</sup>

<sup>1</sup> Department of Intensive Care, Cliniques St-Luc, Université catholique de Louvain, 1200 Brussels, Belgium

<sup>2</sup> Department of Pathology, Cliniques St-Luc, Université catholique de Louvain, 1200 Brussels, Belgium

<sup>3</sup> Department of Clinical Chemistry, Cliniques St-Luc, Université catholique de Louvain, 1200 Brussels, Belgium

## ABSTRACT

The case is reported of a 39-year-old severely obese woman who developed acute metabolic disorders after the administration of a short course of intravenous amiodarone. The main biological features were hypertriglyceridemia, hypoglycaemia, hyperlactatemia and hyperammonemia; all were reversible after amiodarone discontinuation. There was an associated rise in liver enzymes. However, the influence of co-factors on these metabolic disorders, such as acquired carnitine deficiency, severe obesity, a long-term course of pancreatitis, and abdominal infections, could not be excluded.

**Keywords:** amiodarone, fatty acids, beta-oxidation, hyperammonemia

Received: 14 May 2019 / Accepted: 29 October 2019

## INTRODUCTION

Amiodarone is a class III antiarrhythmic agent that is widely used in clinical practice to treat supraventricular and ventricular arrhythmias. Among the adverse effects of amiodarone, acute hepatotoxicity is a rare but potentially fatal complication [1-6]. A case of severe but reversible metabolic disturbances occurring soon after a short-course of intravenous amiodarone in a critically ill patient, is described.

The clinical pattern was distinct from the hepatic failure exceptionally reported after a short-course of intravenous amiodarone. This acute liver dysfunction may also have been precipitated by co-existing factors such as acquired carnitine deficiency, severe obesity, and a long-term course of pancreatitis complicated by abdominal infections.

## CASE REPORT

A 39-year-old woman weighing 87 kg weight and a body mass index of 34.9 kg/m<sup>2</sup>, was admitted to the intensive care unit (ICU) of a tertiary teaching hospital. (Cliniques universitaires St-Luc, Brussels, Belgium),

for an acute pancreatitis secondary to biliary perforation after endoscopic resection of a duodenal ampulla. The patient had a past medical history of Gardner syndrome (a form of familial adenomatous polyposis associated with mutations in the APC gene) and had previously undergone total colectomy and unilateral adrenalectomy. At the time of admission, laboratory data did not reveal any change in lipid metabolism or in liver function tests including ammonemia. However, two years previously, diffuse liver steatosis had been suspected following a computed tomography examination. Lipid profile was normal at that time.

The clinical course over the first weeks of hospitalisation was characterized by multiple episodes of pancreatitis-related intra-abdominal infections that were treated with antimicrobial therapy, surgery or percutaneous drainage.

Enteral nutrition was started immediately following admission but was limited by a slow gastric emptying and a reduced intestinal transit. Parenteral nutrition was introduced on hospital day twenty-eight. On day thirty-three, the patient presented with recurrent episodes of paroxysmal atrial fibrillation and intravenous amiodarone hydrochloride (CORDARONE®, Sanofi,

Diegem, Belgium) was started with a loading dose of 300 mg and a maintenance dose of 450 mg over a single day. Two days after the loading dose of amiodarone, the patient became encephalopathic and hyperammonemia was documented. The medications administered over the week preceding amiodarone hydrochloride prescription are listed in Table I.

At the same time, there was a significant rise in liver enzymes, namely alkaline phosphatase and gamma-glutamyl transferase, and an increase in plasma triglycerides (Table II).

Parenteral nutrition had been stopped the day before amiodarone had been prescribed. Amino acids were measured by ion-exchange chromatography and post-column derivatization with ninhydrin, and spectrophotometric detection using a Biochrom 30 amino acid analyser™ (Biochrom LTD, Cambridge, UK).

A significant increase in glutamine plus glutamate, consistent with the observed hyperammonemia was recorded. A significant decrease in citrulline was also noted. Organic acids were measured by gas chromatography (Hewlett Packard 5973™, Littleton, CO 80127 USA) after extraction from urine by standard ethyl acetate diethyl ether extraction and derivatization to trimethylsilyl (TMS) derivatives. Lactic and pyruvic aciduria was recorded, as was a moderate hyper excretion of 3-hydroxybutyric acid. Arterial lactate increased to 15 mmol/L.

The treatment for this outcome consisted of carnitine supplementation (Cliniques St-Luc Hospital Pharmacy, Brussels, Belgium) 100 mg/kg as a single dose, and sodium benzoate (Cliniques St-Luc Hospital Pharmacy, Brussels, Belgium) administration, 12 g/day for seven days. The total daily dose of glucose infusion was

**Table I. List of the medications prescribed over the week preceding amiodarone hydrochloride prescription**

Medications
Vancomycin (Mylan, Hoeilaart, Belgium)
Ceftazidim (Kefadim®, Eurocept Pharmaceuticals, Ankeveen, The Netherlands)
Piperacillin-tazobactam (Mylan, Hoeilaart, Belgium)
Amoxicillin (Clamoxyl®, Sandoz, Vilvoorde, Belgium)
Metronidazole (B Braun Medical, Diegem, Belgium)
Cefuroxime (Zinacef®, GlaxoSmithKline Pharmaceuticals, Wavre, Belgium)
Temocillin (Negaban®, Eumedica SA, Manage, Belgium)
Insulin (Actrapid®, Novo Nordisk, Brussels, Belgium)
Norepinephrine (Aguettant SA/NV, Brussels, Belgium)
Nadroparine (Fraxiparine®, Movianto, Aspen, USA)

**Table II. Laboratory data before Day 0, and after amiodarone administration**

	Day 0	Day 2	Day 3	Day 4	Day 5	Day 6	Day 7	Day 8	Day 9	Day 10	Day 11	Day 12
GGT (NV=<40 IU/L)	65	126	305	700	1172	1640	1874	1507	1520	1160	1267	990
Alkaline phosphatase (NV=35-105 IU/L)	125	250	369	540	659	734	736	636	626	560	673	549
AST (NV=13-35 IU/L)	29	114	80	35	28	23	24	20	22	22	21	17
ALT (NV=7-35 IU/L)	15	19	41	56	57	50	41	40	37	35	37	37
Total bilirubin (NV=<1.2 mg/dL)	0.9	1.1	1.1	1.3	1.4	1.3	1.2	1.2	1.1	0.9	0.9	0.9
INR (NV=0.80-1.20)	2.09	2.11	1.57	1.59	1.47	1.4	1.36	1.35	1.32	1.26	1.26	1.27
Ammoniaemia (NV=<90 µg/dL)	-	179	167	155	139	153	99	79	97	88	111	63
Triglycerides (NV=< 150 mg/dL)	-	-	454	438	498	608	604	-	444	338	303	223
Arterial lactate (NV=<2.2 mmol/L)	-	10.4	2.9	2.0	1.3	1.4	1.9	2.0	1.5	1.4	1.9	1.9
Urine lactate (NV=<50 mmol/mmol creatinine)	-	1190	-	-	-	-	-	-	-	-	-	-
Parenteral nutrition	Stop	-	-	-	-	-	-	-	-	-	-	-
Enteral nutrition	No	No	500 ml	No	500 ml	500 ml	500 ml	500 ml	500 ml	500 ml	500 ml	500 ml
Glucose supplementation	-	Yes	Yes	Yes	Yes	Yes	Yes	Yes	Yes	Yes	Yes	Yes

GGT, gamma-glutamyl transferase; AST, aspartate aminotransferase; ALT, alanine aminotransferase; INR, International Normalized Ratio. Enteral nutrition (Peptamen HN, Nestlé® HealthScience): proteins 20% (33 g/500 ml), glucose 47%, lipids 33% (24.5 g/500 ml, 70% of fat as medium-chain triglycerides). Enteral nutrition consisted of Peptamen HN (Nestlé® HealthScience Belgique, Brussels, Belgium) proteins 20% (33 g/500 ml), glucose 47%, lipids 33% (24.5 g/500 ml, 70% of fat as medium-chain triglycerides).

increased, with additional supplementation of hypertonic glucose to control episodes of hypoglycemia.

Three days after the administration of amiodarone, the enteral nutrition was progressively reintroduced.

Continuing correction of metabolic disorders characterized the further biological course. Parenteral nutrition, including a moderate dose of lipids, was resumed on day fourteen, to complete enteral nutrition. This approach was well tolerated.

## ■ DISCUSSION

In addition to the common metabolic disorders observed during the course of acute pancreatitis complicated by multiple infections, this patient presented less common metabolic manifestations. The primary documented disorders were hypertriglyceridemia, hypoglycaemia, hyperlactatemia and hyperammonemia. These findings were suggestive of disorders of fatty acids oxidation (FAO), hypertriglyceridemia and hypoglycemia, together with inhibition of the mitochondrial respiratory chain (hyperlactatemia) and urea cycle (hyperammonemia).

The common causes for these disorders were investigated and particularly the potential role of drug prescription and nutritional status. Hypertriglyceridemia and hyperammonemia were associated with a rise in liver enzymes, mainly alkaline phosphatase, and hepatic dysfunction was therefore suspected.

Oral long-term use of amiodarone may be complicated by an asymptomatic rise in serum transferase concentration in up to 25% of treated patients [7]. The steatotic pattern of drug-induced liver injury is well-known in patients with long-term administration of amiodarone and occurs after several months or years of treatment [8]. Steatosis during amiodarone therapy may result from impaired  $\beta$ -oxidation [8-9]. By contrast, acute hepatotoxicity following intravenous loading appears exceptional, and the possible role of the solvent has been discussed [10-15]. Usually, liver injury is rapidly reversible after discontinuation of amiodarone [2]. However, amiodarone can also cause fulminant hepatic failure, especially following a high-dose intravenous administration. Lethal cases presented massive hepatic necrosis on their histology, which was not observed in the current case [1-6].

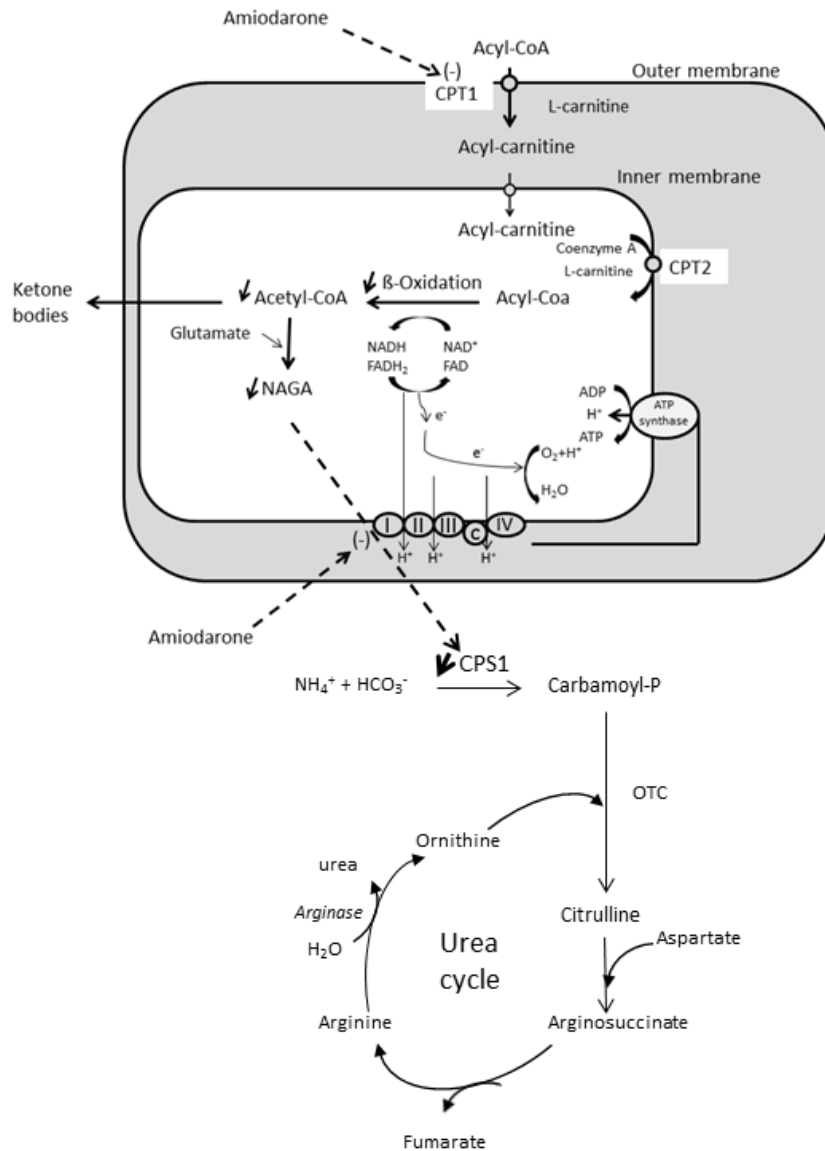
Drugs associated with mitochondrial toxicity and failure of aerobic metabolism usually produce microvesicular steatosis with minimal inflammation and ne-

crosis at liver biopsy [16]. These changes may develop within days of the administration of aspirin) or weeks in the case of linezolid. By contrast, amiodarone is usually considered to cause chronic liver injury. Amiodarone can induce steatohepatitis-like liver damage which can eventually lead to cirrhosis [17]. Amiodarone-induced liver injury is associated with both microvesicular steatosis and macrovascular steatosis as a consequence of impaired mitochondrial function and inhibition of fatty acids oxidation [8,9].

Amiodarone is an amphiphilic drug with protonable amine moiety that favours its accumulation inside the mitochondrial matrix. In amiodarone, the benzofuran-phenyl methanone moiety could be the chemical structure responsible for mitochondrial dysfunction [18]. The drug has been shown to have a dual action on fatty acids oxidation [18,19]. Amiodarone, at least in some *in vitro* models, is a direct inhibitor of carnitine-palmitoyl transferase 1 (CPT1) [20]. This would result in a reduced availability of acylcarnitine, with in turn, reduced plasma ketone bodies, accumulation of plasma acylcarnitine derivatives and urine dicarboxylic acids, and severe hypoglycaemia [17,22]. The decrease of acetyl-CoA formation would also reduce the availability of N-acetyl glutamic acid (NAGA), a substrate for carbamoyl phosphate synthetase (CPS1), and reduce ammonia clearance. Amiodarone could also impair fatty acids oxidation by the inhibition of the mitochondrial respiratory chain activity at the level of complexes I and II [19-21] It is also to be noted that in our patient, the endogenous synthesis of carnitine could have been reduced by malabsorption, sepsis and organ failure [23].

The possible role of pre-existing liver steatosis and obesity may also be considered [24,25]. Obese individuals may present a higher risk of drug-induced liver injury, but this is unlikely in the case for amiodarone [26]. Additionally, a review of the literature suggests that, among the medications prescribed to the patient during the week before the onset of the most recent and unexpected metabolic disorders, no drug other than amiodarone had the ability to inhibit CPT1.

In the present case report, the mechanism causing hyperammonemia remains speculative (Figure 1). Ammonia production by intestinal bacteria was unlikely as previously the patient had a total colectomy. The absence of an inborn error of metabolism in the urea cycle was also verified. Carnitine is also indirectly required for the proper functioning of the urea cycle.



**Fig. 1. (Adapted from [22,23]). Possible mechanisms of amiodarone-induced hypertriglyceridemia and hyperammonemia.** Amiodarone is recognized as a potential inhibitor of carnitine-palmitoyl transferase 1 (CPT1). This will result in a reduced availability of acylcarnitine, with impaired beta-oxidation and acetyl-CoA production. Amiodarone also impairs the mitochondrial respiratory chain activity at the level of complexes I and II. The decrease in acetyl-CoA may also reduce the availability of N-acetyl glutamic acid (NAGA), a substrate for carbamoyl phosphate synthetase (CPS1).

The synthesis of N-acetyl glutamic acid (NAGA), an important cofactor of carbamoyl phosphate synthetase (CPS1), produced from acetyl-CoA and glutamate by NAGA synthetase, is decreased.

Finally, there is no documented relationship between anomalies in the FAO or urea cycle and Gardner's syndrome.

## CONCLUSION

In conclusion, even a short course of amiodarone therapy may disturb some metabolic pathways, mainly

FAO. The reasons why the present patient was so susceptible to this remains speculative as amiodarone is widely and safely prescribed in ICU patients with various medical conditions. Genetic predisposition could not be excluded. Other factors are probably involved and this would be particularly the case for critically ill patients presenting with associated causes for acquired carnitine deficiency such as sepsis or a catabolic state, or pre-existing disorder, including non-alcoholic liver fatty disease.

Reversibility was observed after amiodarone discontinuation.

## ■ INFORMED CONSENT

Written consent was obtained from the patient.

## ■ CONFLICTS OF INTEREST

The authors declare that there is no conflict of interest regarding the publication of this article.

## ■ REFERENCES

1. Kalantzis N, Gabriel P, Mouzas J, et al. Acute amiodarone-induced hepatitis. *Hepatogastroenterology*. 1991;38:71-4.
2. Giannattasio F, Salvio A, Varriale M, et al. Three cases of severe acute hepatitis after parenteral administration of amiodarone: the active ingredient is not the only agent responsible for hepatotoxicity. *Ann Ital Med Int*. 2002;17:180-4.
3. MacFadyen RJ, Palmer TJ, Hisamuddin K. Rapidly fatal acute amiodarone hepatitis occurring in the context of multiple organ failure. *Int J Cardiol*. 2003;91:245-7.
4. Gayam V, Khalid M, Dahal S, et al. Fatal Acute Liver Failure With Intravenous Amiodarone: A Case Report and Literature Review. *Gastroenterology Res*. 2018;11:62-3.
5. Gluck N, Fried M, Porat R. *Acute Isr Med Assoc J*. 2011;13:748-52.
6. Li JG, Yang TC, Yu DM, Ren TH. Fatal acute liver failure after intravenous amiodarone administration. *J Formos Med Assoc*. 2015;114:294-6.
7. Verhovez A, Elia F, Riva A, Ferrari G, Aprà A. Acute liver injury after intravenous amiodarone: a case report. *Am J Emerg Med*. 2011;29:843.e5-6.
8. Fromenty B, Fisch C, Labbe G, et al. Amiodarone inhibits the mitochondrial beta-oxidation of fatty acids and produces microvesicular steatosis of the liver in mice. *J Pharmacol Exp Ther*. 1990;255:1371-6.
9. Lewis JH, Mullick F, Ishak KG, et al. Histopathologic analysis of suspected amiodarone toxicity. *Human Pathol*. 1990;21:59-67.
10. Rätz Bravo AE, Drewe J, Schlienger RG, et al. Hepatotoxicity during rapid intravenous loading with amiodarone: Description of three cases and review of the literature. *Critical Care Med*. 2005;33:128-34; discussion 245-6.
11. Tsuda T, Tada H, Tanaka Y, et al. Amiodarone-induced reversible and irreversible hepatotoxicity: two case reports. *J Med Case Rep*. 2018;12:95.
12. Chan AL, Hsieh HJ, Hsieh YA, Lin SJ. Fatal amiodarone-induced hepatotoxicity: A case report and literature review. *Int J Clin Pharmacol Ther*. 2008;46:96-101.
13. Hashmi A, Keswani NR, Kim S, Graham DY. Hepatic Dysfunction in Patients Receiving Intravenous Amiodarone. *South Med J*. 2016;109:83-6.
14. Diab OA, Kamel J, Abd-Elhamid AA. Predictors of intravenous amiodarone induced liver injury. *Egypt Heart J*. 2017;69:45-54.
15. Chen CC, Wu CC. Acute Hepatotoxicity of Intravenous Amiodarone: Case Report and Review of the Literature. *Am J Ther*. 2016;23, e260-3.
16. Hoofnagle JH, Björnsson ES. Drug-Induced Liver Injury - Types and Phenotypes. *N Engl J Med*. 2019;381:264-73.
17. Begriche K, Massart J, Robin MA, Borgne-Sanchez A, Fromenty B. Drug-induced toxicity on mitochondria and lipid metabolism: mechanistic diversity and deleterious consequences for the liver. *J Hepatol*. 2011;54:773-94.
18. Spaniol M, Bracher R, Ha HR, Follath F, Krähenbühl S. Toxicity of amiodarone and amiodarone analogues on isolated rat liver mitochondria. *J Hepatol*. 2001;35:628-36.
19. Fromenty B, Fisch C, Berson A, et al. Dual effect of amiodarone on mitochondrial respiration. Initial protonophoric uncoupling effect followed by inhibition of the respiratory chain at the levels of complex I and complex II. *J Pharmacol Exp Ther*. 1990;255:1377-84.
20. Kennedy JA, Unger SA, Horowitz JD. Inhibition of carnitine palmitoyltransferase-1 in rat heart and liver by perhexiline and amiodarone. *Biochem Pharmacol*. 199;52:273-80.
21. Felser A, Blum K, Lindinger PW, Bouitbir J, Krähenbühl S. Mechanisms of hepatocellular toxicity associated with dronedarone--a comparison to amiodarone. *Toxicol Sci*. 2013;131:480-90.
22. Massart J, Begriche K, Buron N, et al. Drug-induced inhibition of mitochondrial fatty acid oxidation and steatosis. *Curr Pathobiol Rep*. 2013;1:147-57.
23. Lheureux PE, Hantson P. Carnitine in the treatment of valproic acid-induced toxicity. *Clin Toxicol (Phila)*. 2009;47:101-11.
24. Begriche K, Massart J, Robin MA, et al. Mitochondrial adaptations and dysfunctions in nonalcoholic fatty liver disease. *Hepatology*. 2013;58:1497-507.
25. Massart J, Begriche K, Moreau C, et al. Role of nonalcoholic fatty liver disease as risk factor for drug-induced hepatotoxicity. *J Clin Transl Res*. 2017;3(Suppl 1):212-32.
26. Mattar W, Juliar B, Gradus-Pizlo I, et al. Amiodarone hepatotoxicity in the context of the metabolic syndrome and right-sided heart failure. *J Gastrointest Liver Dis*. 2009;18:419-23.