

# The Use of Novel Adopters for Acute Rib Fixation in Critical Chest Trauma, Undertaken by Orthopaedic Surgeons: an Observational Cohort Study

Paul J. Jermin\*, James Perry, Sanjay Kalra, Elizabeth Flockton, Henry K. Rourke

Department of Orthopaedics, Royal Liverpool and Broadgreen University Hospitals, Liverpool, United Kingdom

## ABSTRACT

**Background:** Surgical stabilisation of acute rib fractures has recently undergone rapid change in the UK with respect to what type of injury is surgically stabilised and who undertakes the operation. This paper presents a review of the literature on surgical fixation and presents our early clinical experience using a recently introduced stabilising system.

**Methods:** Data was prospectively collected from the first 10 patients undergoing surgical stabilisation of acute rib fractures using the Synthes Matrix RIB plating system. The data included demographics, Injury Severity Score, length of stay in Intensive Care, length of time on a ventilator, analgesic requirements, pneumonia rates and mortality. Patients were followed up until they were discharged from hospital.

**Results:** Patients had an average Injury Severity Score of 26 (16-57), the average number of ribs fractured was 8.2 (4-14), nine patients had flail chest and one had multiple fractures, mean time from injury to fixation was 2.8 days. In the reported cohort, there were no deaths, two pneumonias (one had pneumonia on presentation). The average length of stay on a ventilator was three days and the average length of stay in Intensive Care was ten days.

**Conclusion:** The early results of this procedure are encouraging. We feel that the modern implants will provide superior results to the highly variable implants that have previously been used. Our results support the literature, showing that with this system, there is a decrease in mortality and morbidity and a decrease in the length of time on a ventilator and stay in Intensive Care.

**Keywords:** Flail chest, rib fracture, MatrixRIB implant, osteosynthesis, early results, cohort study

Received: 15 May 2015 / Accepted: 05 July 2015

## INTRODUCTION

Rib fractures are common in trauma patients and can be a life-altering or terminal event. Mortality has been shown to be directly proportional to the number of ribs fractured [1]. A flail chest is defined when a rib or ribs presents with at least three consecutive ribs fractures [2]. This creates a free segment of the thoracic wall that moves independently, and often paradoxically. These altered mechanics, with the accompanying pain, results in decreased tidal volume and cough, which in turn can result in atelectasis, pneumonia, acute respiratory

distress and need for mechanical ventilation [3]. It has been reported that rib fractures occur in 30-40% and flail chest occurs in 10% of blunt thoracic wall trauma, with mortality from flail chest reported to be as high as 33% [2].

Traditionally, rib fractures have been managed with aggressive non-operative treatment, the goals of which are pain relief and optimization of lung volume. The approach to pain relief for this type of patients has developed with time and at present there are numerous modalities available. The use of epidural anaesthesia has increased and has been found to provide better

\* James Perry: Department of Orthopaedics, Royal Liverpool and Broadgreen University Hospitals, Liverpool, United Kingdom, Prescot Street, Liverpool L7 8XP, UK  
 \* Sanjay Kalra: Department of Orthopaedics, Royal Liverpool and Broadgreen University Hospitals, Liverpool, United Kingdom, Prescot Street, Liverpool L7 8XP, UK  
 \* Elizabeth Flockton: Department of Orthopaedics, Royal Liverpool and Broadgreen University Hospitals, Liverpool, United Kingdom, Prescot Street, Liverpool L7 8XP, UK  
 \* Henry K. Rourke: Department of Orthopaedics, Royal Liverpool and Broadgreen University Hospitals, Liverpool, United Kingdom, Prescot Street, Liverpool L7 8XP, UK  
 \* Correspondence to: Paul J Jermin, Department of Orthopaedics, Royal Liverpool and Broadgreen University Hospitals, Liverpool, United Kingdom, Prescot Street, Liverpool L7 8XP, UK;  
 e-mail: pauljermin@hotmail.com

subjective pain relief and to improve pulmonary function tests (PFTS) [4]. A meta-analysis found that, despite this, epidural anaesthesia offered no reduction in mortality, the length of stay (LOS) in an intensive care unit (ICU) or hospital LOS [5]. The National Trauma Data Bank found only 8% of patients in the USA had placement of an epidural catheter for flail chest [6].

As well as pain relief, other modalities of treatment are employed to treat these patients, such as chest physiotherapy (with incentive spirometry and cough assisting devices); non-invasive ventilation pulmonary toilet (though there is minimal data to support its usage); mechanical ventilation and tracheostomy. Due to the limitations of non-operative treatment of these patients, clinicians have turned to surgery in an attempt to improve results.

Surgical management of rib fractures has been evolving. Historical procedures include mechanical respirators and traction devices and rib fractures have traditionally been treated by cardiothoracic surgeons, many of whom have neither seen nor assisted in such surgery and only 22% being aware of any randomised controlled trials on the subject [6]. Recently there has been a move in parts of the UK and USA, and elsewhere, for orthopaedic surgeons, with the support of their cardiothoracic colleagues, have taken ownership of the surgical management of acute rib fractures as part of a major trauma multidisciplinary team. Over the last few decades, more sophisticated techniques have been used and there has been a growing body of evidence on the surgical management of these injuries, mostly around flail chest. The devices used to fixate ribs vary including K-wires, struts and sutures. The introduction of rib specific plates has generally lead to these methods becoming unfashionable. Recent studies have described biomechanical testing, implant design and surgical techniques for several plate designs [7-10].

## Indications for Rib Fixation

### 1. Flail Chest

In 2013, two meta-analyses were published specifically looking at surgical management of flail chest [11,12]. They both found that the data pool was limited and based mainly on small retrospective studies. The conclusions reached by both meta-analysis was that encouraging results were obtained with all modes of fixation. Slobogean et al found, with surgical fixation, a mean decrease in ventilator days of eight days, an odds ratio (OR) of developing pneumonia of 0.2, decreased

ICU LOS mean of five days, mortality OR 0.31, tracheostomy OR 0.06 and chest wall deformity OR 0 [11].

Leinicke et al [12] reported similar results with fewer days on mechanical ventilation (DMV), effect size (ES) -4.52 days, ICU LOS -3.4 days, decreased mortality RR0.44 and pneumonia 0.45. The evidence in both these papers is compellingly in favour of fixation of flail chest, but both concluding that further studies were required. Additionally they did not clarify many of the fine details of management, such as when is the best time to fixate. what is the best device and whether all fractures need to be fixated.

There is some “level 2” evidence (prospective randomised controlled trials) in favour of fixation of flail chests.

### 2. Multiple Rib Fractures

In 2005 Flagel et al looked at over 70,000 thoracic wall

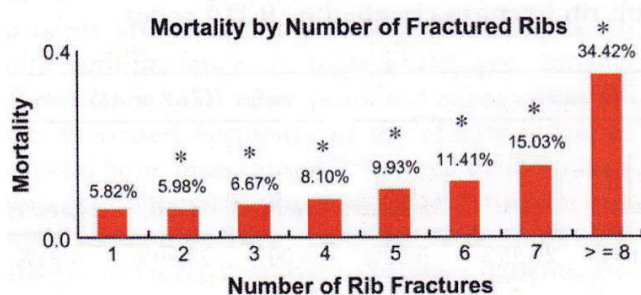


Figure 1. Mortality by number of fractured ribs

injuries and found that there was a direct correlation between number of ribs fractured and mortality [1].

Other studies have arrived at similar conclusions. Bergeron et al [13] found that if more than 6 ribs are fractured, mortality increases eight fold, Holcomb et al [14] found that morbidity increased significantly in patients over forty five years of age and with more than four ribs fractured and Barnea et al [15] found a significant rise in morbidity and mortality if more than three ribs are fractured. There is “level 3 and 4” evidence (retrospective and prospective cohort studies) that fixation of multiple rib fractures improves outcome.

### 3. Acute Pain and Disability

It has been hypothesised that patients experiencing persistent, unrelenting pain with breathing, coughing or mobilisation may benefit from fixation [16-18]. Interestingly, Fabricant et al [18] found that one of the most predictive factors for chronic pain after rib fractures is the intensity of pain during the acute post-injury

ry period. The benefit of fixation of rib fractures solely for pain has yet to be definitively demonstrated in the literature.

#### 4. Deformity, Non or Mal Union

Rib fractures with significant displacement can lead to symptomatic mal-unions which can also give rise to chest wall deformity. These can be treated surgically with osteotomy and deformity correction to restore the normal contour and volume of the thorax [19,20]. Symptomatic non-union is another relative indication for surgical intervention. In the presence of multiple rib fracture non-unions, upper extremity motion or thoracic wall movement during respiration can lead to debilitating pain and dyspnoea on exertion, with symptomatic resolution following surgical correction [19,20].

#### 5. Pulmonary Contusions

A pulmonary contusion, in association with a flail chest, has been proposed to be a contraindication to surgical fixation [21]. Well intentioned as this study was, there were limitations in the power of the study and the true evaluation of the contribution of contusion to rib fracture fixation remains in question. Althausen et al [22] demonstrated a trend that surgical stabilisation in patients with pulmonary contusions improved outcomes compared with the non-operatively treated patients. Tanaka et al [23] found no difference in pulmonary contusions between their randomised controlled groups of patients who had surgical or no-surgical management suggesting that they do not play a significant role in determining treatment.

#### 6. Timing

An unidentified factor in treatment is the best time to perform surgery on patients with pulmonary contusions. Results from several studies have suggested that earlier fixation leads to shorter stays in ICU [22-24]. There appears to be a move away from waiting for the patient to deteriorate and then fixing their fractures, towards operating early to prevent any deterioration. However, at present, the optimal time for fixation is debatable, though there does appear to be benefits from early fixation, prior to deterioration, including less time on a ventilator; reduced pneumonia and quicker recovery from pneumonia.

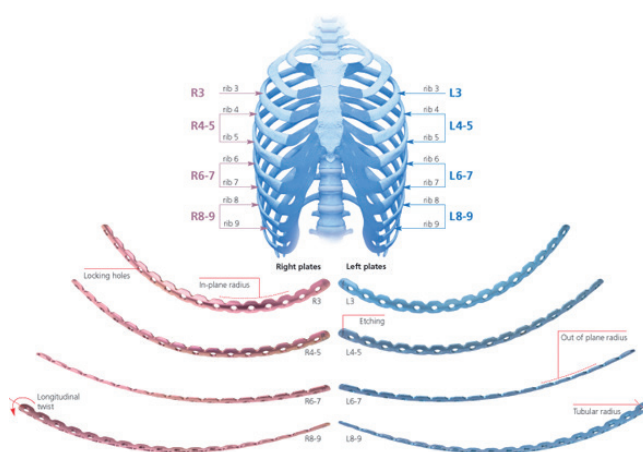
The present study was undertaken in a UK University Hospital which is part of a regional Collaborative Major Trauma Centre serving a population of approximately 2 million. In this region, the cardiothoracic

centre is on a standalone site, geographically separate from accident and emergency departments. Following a peer review recommendation to improve outcomes from thoracic trauma, the collaborative partners developed a standard operating procedure for rib fractures within a wider thoracic trauma management protocol. After undergoing specialised training on the Synthes Matrix rib fixation course and increasing awareness in the hospital about this technology, rib fixations using this technique commenced in August 2014, initially with a cardiothoracic surgeon present for the first few cases. Prior to the introduction of surgical stabilisation, an internal audit of twenty patients showed there was a mortality rate of 27% for patients with flail chest, ICU LOS thirteen days, 85% required mechanical ventilation. These data supported results recorded in the wider literature.

## METHODS

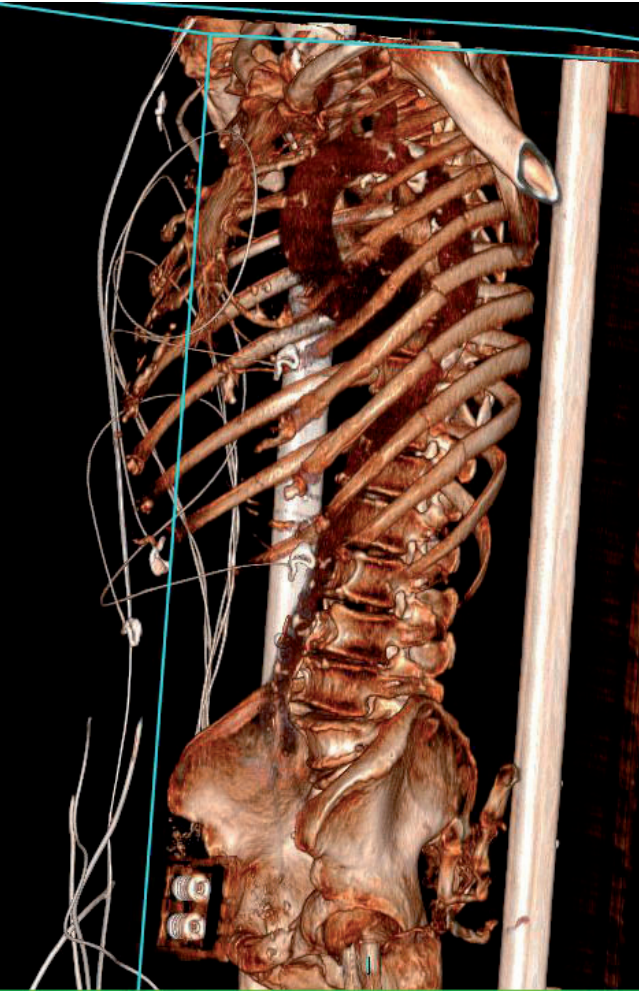
From August 2014 to May 2015 data were collected prospectively from all patients who underwent rib fixation. This included, looking at basic demographics (age, sex), analgesia requirements, pre and post fixation observations, oxygen requirements, number of ribs fractured, time to fixation, and complications. Patients were followed up to the point of discharge from hospital.

All patients underwent pre-operative CT scanning with three dimensional reconstruction views. All patients were fixated using Synthes Matrix RIB plates, which are pre-contoured, anatomical locking titanium rib plates. This system comprises pre-contoured tita-



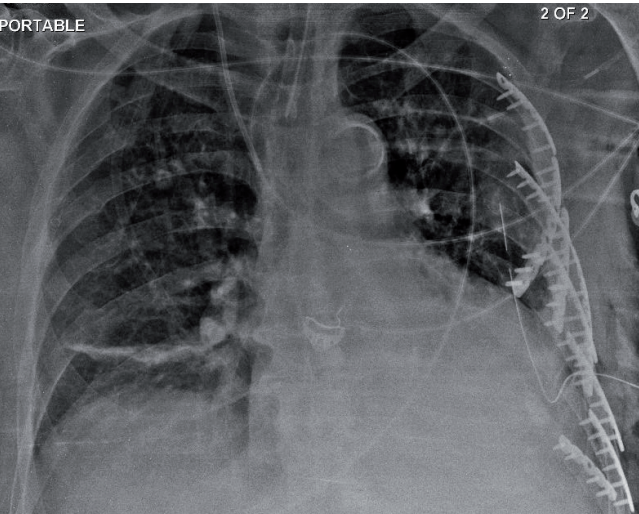
**Figure 2. The Synthes Matrix RIB Plating system, pre-contoured titanium alloy locking low profile 1.5 mm thick plates with 2.9 mm diameter locking screws**





**Figure 3. CT reconstruction of flail chest from multiple segmental left sided rib fractures**

nium alloy locking low profile 1.5 mm thick plates with 2.9 mm diameter locking screws (Figure 2). Figure 3



**Figure 4. The same patient as shown in figure 2, after plating**

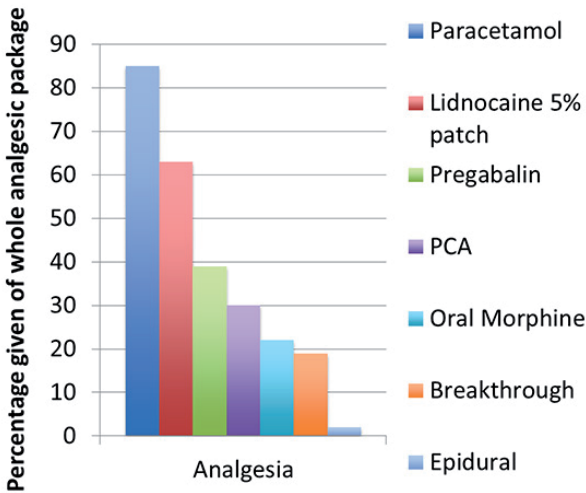
shows a CT reconstruction of flail chest from multiple segmental left sided rib fractures. Figure 4 shows the same patient as shown in figure 2, after plating. All patients had input from the acute pain services and physiotherapists and were assessed the day after admission, with the aim of achieving fixation within five days of injury. The proportional breakdown of analgesia given post-operatively is given in Figure 5.

The indications for fixation are flail segments and multiple (more than three) displaced rib fractures. Other additional factors that were considered are: problems with pain control or thoracic mobilisation, increasing respiratory support, haemo/pneumothorax or gross chest wall deformity.

Peri-operatively, all patients had routine thromboprophylaxis including low dose dalteparin, anti-embolism stockings, adequate fluid resuscitation and where appropriate, early mobilisation as well as chest drain placement for a minimum of twenty hours and post-operative chest radiographs.

## ■ RESULTS

Ten patients underwent fixation during this period. Five were male and five were female, the average age was 62 (46-83). Six patients had suffered a fall from a height, one from a fall from standing height, two from road traffic collisions and one had been physically assaulted. The average Injury Severity Score (ISS) was 26 (range 16-57). There were two pneumothoraces, five haemopneumothoraces and three haemothoraces present in this cohort. Nine patients had a flail chest with a mean of 8.2 ribs fractured per patient (4-14) and the



**Figure 5. Mean proportional breakdown of analgesia given post-operatively**



mean length of time to fixation was 2.8 days from injury [2-8].

There were no deaths. There were two pneumonias at three days post operatively, although one (delayed presentation after a fall at home) had pneumonia on arrival in at hospital. The mean LOS on a ventilator was three days and mean LOS in ICU was ten days. The literature on conservative management would suggest that a ten patient cohort should have reported 2-4 deaths; 3-6 pneumonias; ventilator LOS 10 days and ICU LOS 18 days.

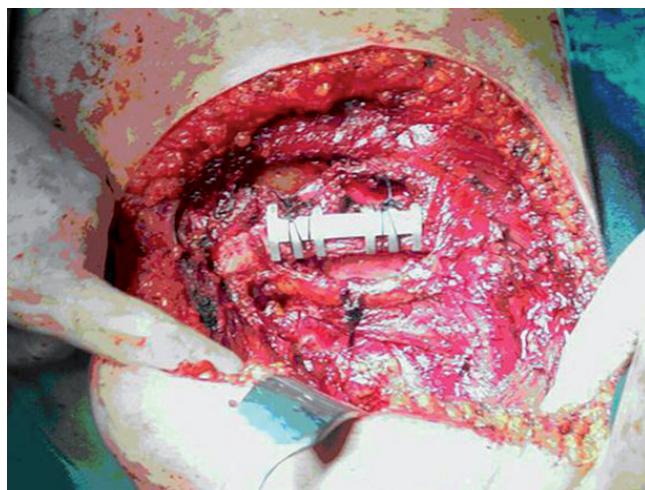
All patients were surgically approached in the lateral position. Using a longitudinal mid-axillary incision, the anterior border latissimus dorsi was identified and reflected and the serratus anterior was split at each level to reveal the fractures.

## ■ DISCUSSION

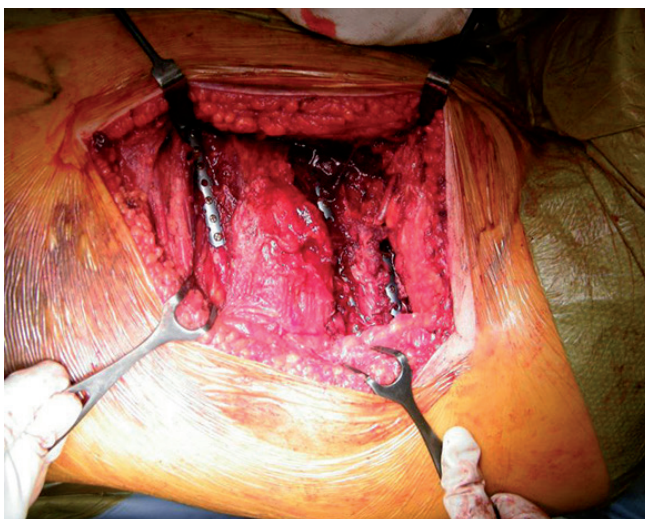
There is a growing and compelling body of evidence in favour of rib fixation in the presence of a flail chest. There may be other conditions which could benefit from fixation such as multiple rib fractures, painful rib fractures, fractures associated with increasing respiratory requirements, but definitive evidence in favour of these is currently lacking.

Most studies looking at flail chest have used early technology to achieve osteosynthesis. The Matrix RIB system offers many theoretical advantages over these. They form a strong construct but with the necessary elasticity to comply with thoracic wall motion. Unlike the Judet struts used previously, they do not require circumferential exposure of the rib and are therefore more preserving of the intercostal muscles and are more protective of their neurovascular bundles. They are pre-contoured, side and site specific making them a more conforming implant. The kit comes with a stop on the drill to minimise the risk to the underlying lung and pleura. Figure 6 shows Judet struts in vivo and the Matrix RIB Plates in vivo, are shown in Figures 7 and 8.

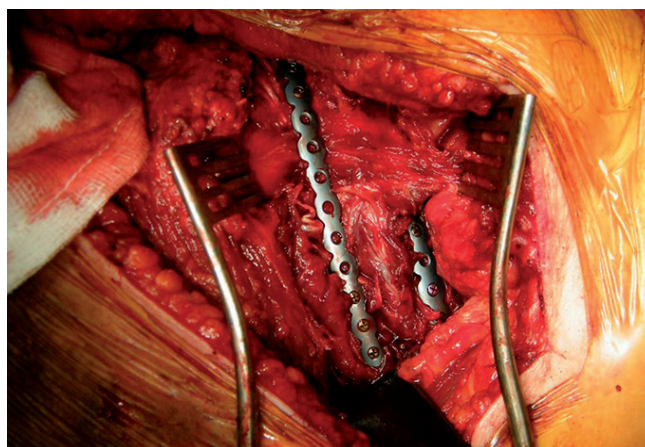
It has been shown that this technology can be safely adopted by orthopaedic surgeons, and even in our early experience of this, our outcomes are very encouraging. The reported data from this study showed there were no deaths, two pneumonias at three days post operatively, although one (delayed presentation after a fall at home) had pneumonia on arrival in at hospital. The mean LOS on a ventilator was three days and mean LOS in ICU was ten days. Compared to previous results on



**Figure 6. Judet struts in vivo**



**Figure 7. Matrix RIB Plates in vivo**



**Figure 8. Matrix RIB Plates in vivo**

conservative management as reported in the literature, where it has been suggested that in a ten patient cohort, the expectations are that there would be two to four deaths, three to six pneumonias, ten days on ventilator

LOS, and eighteen days ICU LOS, the current results are very encouraging.

It is worth noting that several other specialities are required in the overall care of these patients, and that to adopt this procedure does require the necessary infrastructure to be in place.

During the writing of this article, a further five fixations have been performed and data from these have not been included in the analysis. However, no deaths and no additional pneumonias were reported. We plan to continue to provide this service and await with interest the results of Matrix RIB system in flail chest, hoping this technology improves upon previous results. We may also look to expand this nascent technology as the indications become clearer to us.

## ■ REFERENCES

1. Flagel BT, Luchette FA, Reed L, et al. Half-a-dozen ribs: the breakpoint for mortality. *Surgery*. 2005;138:717-25.
2. Ciraulo DL, Elliott D, Mitchell KA, Rodriguez A. Flail chest as a marker for significant injuries. *J Am Coll Surg*. 1994;178:466-70.
3. Fitzpatrick DC, Denard PJ, Phelan D, Long WB, Madey SM, Bottlang M: Operative stabilisation of flail chest injuries: Review of literature and fixation options. *Eur J Trauma Emerg Surg*. 2010;36:427-33.
4. Simon BJ, Cushman J, Barraco R, et al. Pain Management Guidelines for Blunt Thoracic Trauma. *J Trauma*. 2005;59:1256-67.
5. Carrier FM, Turgeon AF, Nicole PC, et al. Effect of epidural analgesia in patients with traumatic rib fractures: a systematic review and meta-analysis of randomized controlled trials. *Can J Anaesth*. 2009;56:230-42.
6. Mayberry JC, Ham LB, Schipper PH, Ellis TJ, Mullins RJ: Surveyed opinion of American trauma, orthopaedic, and thoracic surgeons on ribs and sternal fracture repair. *J Trauma*. 2009;66:875-9.
7. Sales JR, Ellis TJ, Gillard J et al. Biomechanical testing of a novel, minimally invasive rib fracture plating system. *J Trauma*. 2008;64:1270-4.
8. Bottlang M, Helzel I, Long W, Madey S. Anatomically contoured plates for fixation of rib fractures. *J Trauma*. 2010;68:611-5.
9. Campbell N, Conaglen P, Martin K, Antippa P. Surgical stabilisation of rib fractures using Inion OTPS wraps – techniques and quality of life follow up. *J Trauma*. 2009;67:596-601.
10. Hasenboeler EA, Bernard AC, Bottiggi AJ et al. Treatment of flail chest with muscular sparing open reduction and internal fixation: description of a surgical technique. *J Trauma*. 2011;71:494-501.
11. Slobogean GP, MacPherson CA, Sun T, Pelletier ME, Hameed SM. Surgical fixation vs nonoperative management of flail chest: a met-analysis. *J Am Coll Surg*. 2013;216:302-11.
12. Leinicke JA, Elmore L, Freeman BD, Colditz GA. Operative management of rib fractures in the setting of flail chest. Systematic review and meta-analysis. *Annals of surgery*. 2013;258:914-20.
13. Bergeron E, Lavoie A, Clas D, et al. Elderly trauma patients with rib fractures are at greater risk of death and pneumonia. *J Trauma*. 2003;54:478-85.
14. Holcomb JB, McMullin NR, Kozar RA, Lygas MH, Moore FA. Morbidity from rib fractures increases after age 45. *J Am Coll Surg*. 2003;196:549-55.
15. Barnea Y, Kashtan H, Skornick Y, Werbin N. Isolated rib fractures in elderly patients: mortality and morbidity. *Can J Surg*. 2002;45:43-6.
16. Cacchione RN, Richardson JD, Seligson D: Painful non-union of multiple rib fractures managed by operative stabilisation. *J Trauma*. 2000;48:319-21.
17. Kerr-Valentic MA, Arthur M, Mullins RJ, Pearson TE, Mulberry JC: Rib fracture pain and disability: Can we do better? *J Trauma*. 2003;54:1058-63.
18. Fabricant L, Ham B, Mullins R, Mayberry. Prolonged pain and disability are common after rib fractures. *Am J Surg*. 2013;205:511-5.
19. Slater MS, Mayberry JC, Trunkey DD: Operative stabilisation of a flail chest six years after injury. *Ann Thorac Surg*. 2001;72:600-1.
20. Botlang M, Long WB, Phelan D, Fielder D, Madley SM: Surgical stabilisation of flail chest injuries with MatrixRIB implants: A prospective observational study. *Injury*. 2013;44:232-8.
21. Voggenreiter G, Neudeck F, Aufmkolk M, Obertacke U, Schmit-Neuerburg KP. Operative chest wall stabilisation in flail chest: Outcomes of patients with or without pulmonary contusions. *J Am Coll Surg*. 1998;187:130-8.
22. Althausen PL, Shannon S, Watts C et al. Early surgical stabilisation of flail chest with locked plate fixation. *J Orthop Trauma*. 2011;25:641-7.
23. Tanaka H, Yukioka T, Yamaguti Y et al. Surgical stabilisation of internal pneumatic stabilisation? A prospective randomised study of management of severe flail chest patients. *J Trauma*. 2002;52:727-32.
24. Nirula R, Diaz JJ, Trunkey DD, Mayberry JC. Rib fracture repair: Indications, technical issues, and future directions. *World J Surgery*. 2009;33:14-22