

Refractory Lactic Acidosis and an Approach to Its Management - A Case Report

Yingke He^{1#}, John Ong^{2#*}, Sharon Ong³

¹ Division of Anaesthesiology, Singapore General Hospital, Singapore

² Department of Engineering, Materials Engineering and Material-Tissue Interactions Group, University of Cambridge, United Kingdom

³ Department of Surgical Intensive Care, Singapore General Hospital, Singapore

ABSTRACT

Background: Lactic acidosis (LA) is a complication of diseases commonly seen in intensive care patients which carries an increased risk of mortality. It is classified by its pathophysiology; Type A results from tissue hypo-perfusion and hypoxia, and Type B results from abnormal metabolic activity in the absence of hypoxia. Reports of the co-occurrence of both types have been rarely reported in the literature relating to intensive care patients. This case report describes the challenging management of a patient diagnosed with both Type A and Type B LA.

Case presentation: A 55-year-old female with newly diagnosed diffuse large B-cell lymphoma (DLBCL) developed hospital-acquired pneumonia, respiratory failure, shock and intra-abdominal septicaemia from a bowel perforation. Blood gases revealed a mixed picture lactic acidosis. Correction of septic shock, respiratory failure and surgical repair caused initial improvement to the lactic acidosis, but this gradually worsened in the intensive care unit. Only upon starting chemotherapy and renal replacement therapy was full resolution of the lactic acidosis achieved. The patient was discharged but succumbed to her DLBCL several months later.

Conclusion: Type A and Type B LA can co-occur, making management difficult. A systematic approach can help diagnose any underlying pathology and aid in early management.

Keywords: lactic acidosis, hyperlactatemia, critical care, intensive care

Received: 12 March 2019 / Accepted: 24 April 2019

BACKGROUND

An underlying disease may cause lactic acidosis (LA), and its presence is associated with an increased risk of mortality [1]. It is a common cause of raised anion gap acidosis in intensive care patients, though it can exist with a normal anion gap [2]. In the latter situation, accurate diagnosis can be difficult. Historically, a serum pH < 7.35 and lactate > 5mmol/L was a widely accepted definition of lactic acidosis [3], however reports in recent literature suggest that overt hyperlactatemia and acidosis are not always apparent in LA [4]. A specific universal definition remains elusive because of variations in cut-off limits between clinical laboratories [4]. Nonetheless, an essential diagnostic criterion is hyperlactatemia or an increase in serum lactate from base-

line albeit still within the normal range. A pH < 7.35 may not always be present in LA because respiratory compensation and alkalosis may occur [4].

LA can be classified into two types based on their pathophysiology; Type A and Type B [4]. Type A LA results from hypoperfusion and tissue hypoxia in conditions such as sepsis, shock, hypovolemia or severe hypoxia, whereas Type B LA results from an imbalance of normal physiological metabolism [4] caused by an underlying disease, drugs or toxins and inborn errors of metabolism. Type B LA can be sub-divided further as Type B1 (disease-associated), Type B2 (drug or toxin associated) and Type B3 (inborn metabolic errors) respectively. At a cellular level, disease mechanisms can differ between the types of LA, e.g. anaerobic respiration versus the Warburg effect in normoxia. Having

* Correspondence to: John Ong, Department of Engineering, Materials Engineering and Material-Tissue Interactions Group, University of Cambridge, Trumpington Street, CB2 1PZ, United Kingdom. E-mail: jo401@cam.ac.uk

Authors with shared co-first authorship.

Type A and Type B LA simultaneously is physiologically possible, although rarely reported in the literature relating to intensive care patients.

This case report describes a challenging case of refractory lactic acidosis arising from respiratory failure, intra-abdominal sepsis and diffuse large B-cell lymphoma (DLBCL) mimicking the features of ischaemic bowel. Subsequently, a recommended structured approach to aid in the diagnosis of its underlying cause(s) in difficult or complicated cases is outlined.

■ CASE PRESENTATION

A 55-year-old female was transferred to the oncology centre for tertiary care. She had a two-week history of abdominal distension and a past medical history of ovarian cancer for which she had had a hysterectomy, bilateral salpingo-oophorectomy and five cycles of chemotherapy more than ten years ago. She was not on any regular medication. Blood tests demonstrated a normochromic normocytic anaemia, healthy liver and kidney function as well as normal clotting limits. Imaging including computerised tomography (CT) with contrast, revealed significant ascites, a moderate right pleural effusion, a 10cm x 8cm x 2.8cm pelvic mass at the distal ileum and normal liver parenchyma. Cytology from a pleuritic tap demonstrated diffuse large B cell lymphoma (DLBCL), consistent with biopsy results from the pelvic mass. The pleural effusion and ascites were then drained successfully without any complications.

One week after her admission, the patient developed a persistent tachycardia and respiratory failure requiring intubation and ventilation in the Intensive Care Unit (ICU). Arterial blood gases revealed metabolic acidosis with respiratory compensation (pH 7.29, CO₂ 29mmHg, pO₂ 77mmHg on 0.5 FiO₂, BE -11.7 HCO₃⁻ 13mmol/L and lactate 5.7mmol/L). The anion gap was mildly elevated at 18 (normal range 8-16mEq/L). A chest X-ray (CXR) performed post-intubation demonstrated pneumoperitoneum and left lower zone lung consolidation (Figure 1).

An emergency exploratory laparotomy was performed without further imaging as the clinical diagnosis was septic shock secondary to perforated gut. Moreover, the patient was progressively drowsy, tachycardic (heart rate 170 beats/min) and hypotensive (blood pressure 82/50 mmHg). Pre-operatively, 500ml fluid boluses were given, increasing the blood pressure to 90/60 mmHg after a total of two litres given. Noradrenaline

(Pfizer Ltd) infusion was started intra-operatively and titrated to a maximum dose of 0.1mcg/kg/min to achieve a mean arterial pressure of 65mmHg. Intra-operative findings confirmed the presence of a pelvic lymphoma, with involvement and perforation of the distal ileum causing feculent peritonitis. The perforated and diseased segment of bowel was resected. Temporary abdominal closure was done given the extensive soilage and oedematous small bowel loops with a view for a relook laparotomy and double barrel stoma in the next two days. Broad-spectrum empirical antibiotics consisting of Vancomycin (Pfizer Ltd) 1gm 12 hourly, Caspofungin (Merck Sharp & Dohme Ltd) 50mg 24 hourly and Meropenem (Pfizer Ltd) 1gm 8 hourly were started intravenously in view of the extensive feculent peritonitis and hospital-acquired pneumonia causing septic shock.

Postoperatively, the patient returned to the ICU and a Fentanyl (AAH Pharmaceuticals Ltd) infusion was started for postoperative analgesia. The Noradrenaline infusion which was started intra-operatively at a dose of 0.1mcg/kg/min, was subsequently weaned off within 24hours. Despite achieving a mean arterial blood pressure target of greater than 65mmHg, a urine output of 0.5-1ml/kg/hr with 2 litres of PlasmaLyte (Baxter Healthcare Ltd) infusion, 20% human albumin solution (Octapharma Ltd) 100ml 24 hourly and being in positive fluid balance, her tachycardia and lactic acidosis did not improve (see Figure 2).

A left shift neutrophilia was noted, but her liver function tests and renal function tests remained nor-

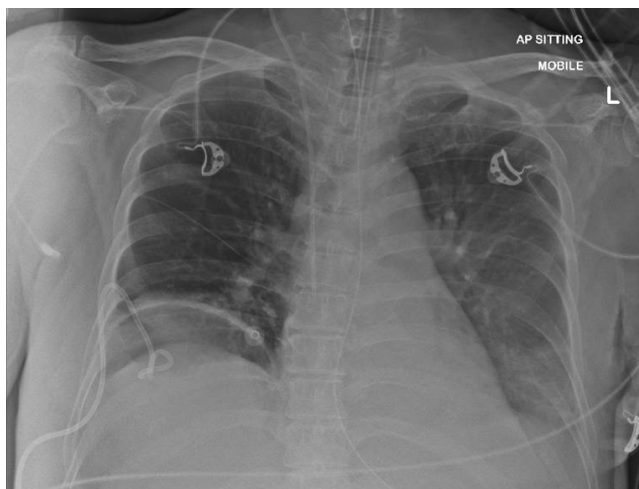


Fig. 1. CXR showing the presence of pneumoperitoneum, left sided consolidation and a right sided chest drain from an earlier insertion for a moderate right sided pleural effusion

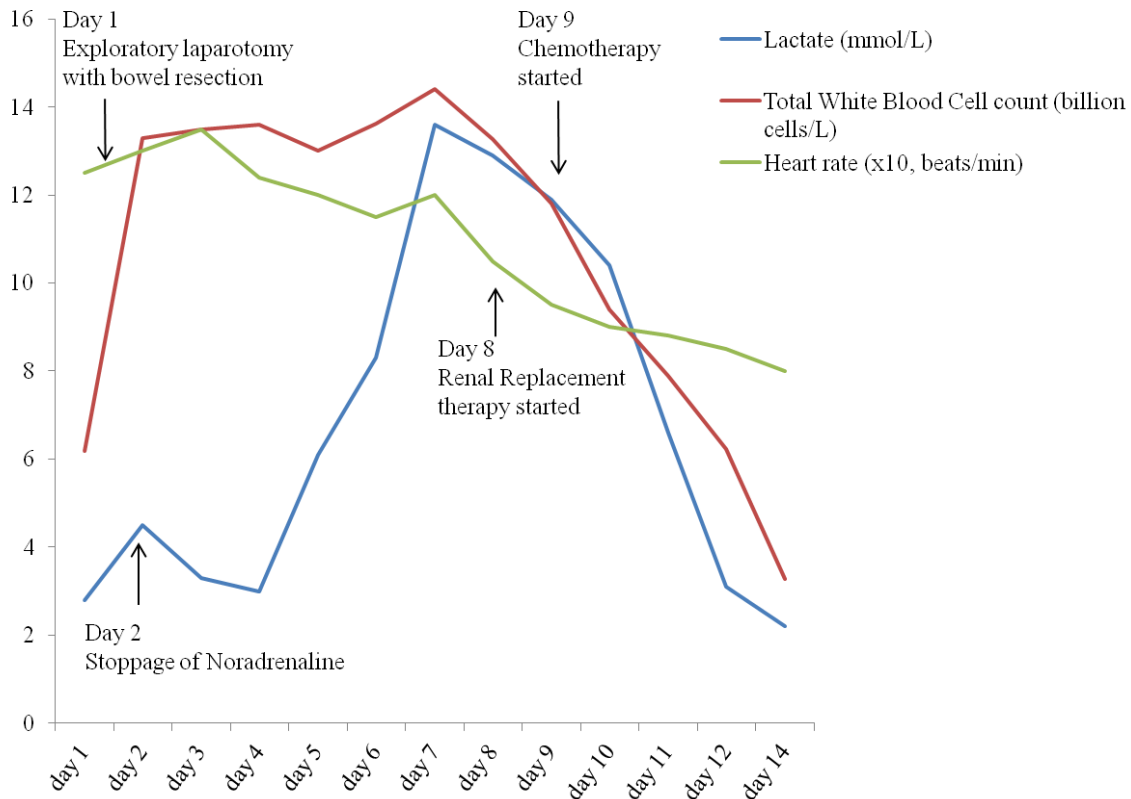


Fig. 2. Trend of serum lactate, total white blood cell count and heart rate (Day 1 = first day of admission to ICU).

mal. After four days in the ICU, the patient's respiratory failure resolved, and the hyperlactatemia plateaued briefly. It was then clear that Type A LA was only contributory to the ongoing lactic acidosis and not the predominant factor. Type B LA from intra-abdominal sepsis was then attributed to the ongoing hyperlactatemia as *Klebsiella pneumoniae*, and *Candida tropicalis* were isolated from her blood cultures. The intravenous Meropenem was promptly changed to intravenous Ceftazidime-Avibactam (Pfizer Ltd) 2.5gm 8 hourly because the isolated *Klebsiella pneumoniae* was found to be Meropenem-resistant. A respiratory wean was attempted, but this was prolonged because of severe tachypnoea - the patient having a spontaneous respiratory rate of 35 to 45 breaths per minute despite adequate tidal volumes generated on pressure support ventilation. This was attributed to respiratory compensation from the lactic acidosis as other causes of tachypnoea such as pain, pulmonary embolism and hypoxia were excluded. A review of the patient's inpatient medications at this point revealed she was on intravenous Vancomycin 1gm 12 hourly, Caspofungin 50mg 24 hourly and Ceftazidime Avibactam 2.5gm 8 hourly and a Fentanyl infusion at a rate of 10-50mcg/hr.

No apparent pharmacological cause for the hyperlactatemia was identified and these medications were given for a total of 10 days.

Due to worsening of the Type B LA, a second laparotomy was performed to rule out bowel ischemia or loculated collections given her initial presentation with bowel perforation, feculent peritonitis and septic shock. However, no abnormalities were found, and the intra-abdominal pressure was noted to be normal (12mmHg). A double barrel stoma was created, and permanent abdominal closure was undertaken. Daily blood investigations done during her stay in the Intensive Care Unit included full blood count, C Reactive protein, procalcitonin, renal panel, liver function test, serum calcium, phosphate and magnesium levels. In addition, echocardiography and chest X-rays were done as clinically indicated. Over time, the biomarkers of infection (white blood cell count, C-reactive protein and procalcitonin) demonstrated a downward trend. After further discussion between the intensivists, general surgeons and oncologists, a serum lactate dehydrogenase (LDH) was performed, and it was found to be elevated at 1002 units/L, suggesting high DLBCL activity. With all other causes of LA addressed,

the worsening Type B LA was attributed to the DLBCL. Continuous renal replacement therapy (CRRT) was commenced to help with the clearance of lactate. Cyclophosphamide, rituximab and etoposide were started as chemotherapy, and complete resolution of the Type B LA was noted one week after. The patient was extubated and transferred out of the ICU 2 weeks after ICU admission but unfortunately succumbed to her DLBCL several months later.

■ DISCUSSION

This patient suffered from Type A and Type B1 LA. Only after weaning off cardio-respiratory support and treating the sepsis did it become apparent that the predominant cause of the patient's lactic acidosis was DLBCL. Interestingly, with the bulk of the disease localised in the pelvis, together with the downward trends of both CRP and PCT, an aggressively and rapidly progressing DLBCL was not initially suspected as the most likely cause of lactic acidosis. Later, the high LDH level and resolution of the other causes of Type B LA were the factors that prompted the commencement of chemotherapy.

LDH, an intracellular enzyme which catalyses the conversion of lactate to pyruvate and vice versa, is an established biomarker for disease activity in non-Hodgkin's lymphoma[5]. However, it is noteworthy that five isoforms of the enzyme exist and these are distributed differently in the organs of the human body [6]. Therefore, there can be many causes of an elevated LDH and determining the sub-type of LDH improves the diagnostic specificity. It is also noteworthy that elevated LDH levels are not directly linked to hyperlactatemia or LA although both signify an underlying pathology.

Lactate exists in two isomers, L-Lactate and D-Lactate. L-lactate is produced by most tissues in the human body and is used as standard measurements in clinical practice. D-lactate is produced by bacteria in the large bowel and diseases such as short bowel syndrome can increase serum D-lactate levels.

Concerning this case, the discussion has been limited to L-lactate. Under anaerobic conditions, L-lactate is an end product of glycolysis cycle and is used as a substrate for gluconeogenesis. Therefore, in tissue hypoperfusion and hypoxia, cellular lactate production is increased, and this results in hyperlactatemia. However, cellular lactate production can be increased by different

mechanisms in the absence of hypoxia. For example, many malignancies, not limited to DLBCL, have been associated with hyperlactatemia through what has been termed the "Warburg effect" [7]. The Warburg effect describes the propensity of cancer cells to convert incoming glucose to lactate in aerobic respiration preferentially [8]. Though its mechanisms were previously poorly understood, recent research has demonstrated that in cancer cells, aberrant changes to genes Myc, Ras, Akt and p53, lead to the over-expression of glycolytic enzymes and glucose transporters thus resulting in increased cellular lactate production [9-18]. This strategic use of lactate as an energy source contributes to the survival of rapidly dividing cancer cells.

The monitoring of serum lactate undoubtedly provides essential information regarding the diagnosis of disease as well as the response to treatment in critically ill patients. However, there is an ongoing debate as to whether arterial or venous sampling should be used. A PubMed literature search using the search terms "systematic review", "arterial", "venous" and "lactate" revealed only two systematic reviews and meta-analyses directly comparing the two methods.

Kruse et al. (2001) concluded that arterial lactate sampling is the gold standard, but venous sampling also is advantageous in detecting hyperlactatemia and therefore should be used as a screening tool. However, they acknowledged that venous sampling was associated with higher lactate values compared to arterial values and that a universal cut-off value could not be established reliably by the study [19]. Bloom et al. (2014) concluded that peripheral venous sampling has a good correlation to arterial sampling within "normal" ranges, but a poor agreement exists between arterial and venous lactate at abnormal values [20]. It is opined that although peripheral venous sampling is an acceptable method of screening for hyperlactatemia, arterial or central venous lactate [21] is better suited for diagnosing and monitoring the disease.

We also agree with Kraut and Madias [4] that universal parameters and consensus to define lactic acidosis are lacking [22], and it is likely that the issues discussed by Kruse et al. (2001) and Bloom et al. (2014) have contributed to this. Thus, there is ambiguity in the distinctions between lactic acidosis and hyperlactatemia since lactic acidosis can be present with a normal pH and the serological values of lactate cannot be used strictly to distinguish the two. Setting clinical definitions aside, hyperlactatemia and lactic acidosis are, physiologically,

two ends of a spectrum where excessive lactate causes acidosis as the underlying aetiology worsens. It is, therefore, reasonable to view hyperlactatemia and lactic acidosis as a single entity in clinical practice since definitions are not robust and do not alter management significantly.

In summary, the downward trend and resolution of hyperlactatemia remain important in goal-directed therapy since elevated levels are associated with increased mortality [23, 24] — the correction of hyperlactatemia hinges on the treatment of the underlying cause. Vasopressors, fluid replacement or mechanical ventilation can help improve Type A LA whereas the treatment of Type B LA can prove more challenging. Intravenous bicarbonate and hemodialysis both have been used to control lactic acidosis as bridging therapies while allowing time for ongoing treatment such as chemotherapy to take effect in this case. Adverse effects of intravenous bicarbonate treatment include hypernatremia and hypervolaemia, and clinicians must be vigilant for these. Renal replacement therapies, both in the form of peritoneal dialysis and hemofiltration have also been widely used for lactate clearance and the correction of associated metabolic acidosis.

■ CONCLUSION

Type A and Type B LA can co-occur. Diagnosing the cause of LA in critically ill patients can be challenging in complex cases, and the monitoring of lactate can be a valuable marker of disease activity or treatment response. Viewing hyperlactatemia and lactic acidosis as a single clinical entity, adopting a structured approach and early multi-disciplinary input can improve clinical management and patient outcomes.

We propose a structured approach to aid clinicians in the early management of hyperlactatemia and LA in Annex 1.

■ CONFLICT OF INTEREST

None to declare.

■ REFERENCES

- Jung B, Rimmel T, Le Goff C, et al. Severe metabolic or mixed acidemia on intensive care unit admission: incidence, prognosis and administration of buffer therapy. a prospective, multiple-center study. *Crit Care*. 2011;15(5):R238.
- Iberti TJ, Leibowitz AB, Papadakos PJ, Fischer EP. Low sensitivity of the anion gap as a screen to detect hyperlactatemia in critically ill patients. *Crit Care Med*. 1990;18:275-7.
- Fall PJ, Szerlip HM. Lactic acidosis: from sour milk to septic shock. *J Intensive Care Med*. 2005;20:255-71.
- Kraut JA, Madias NE. Lactic Acidosis. *New Eng J Med*. 2014;371:2309-19.
- Ferraris AM, Giuntini P, Gaetani GF. Serum lactic dehydrogenase as a prognostic tool for non-Hodgkin lymphomas. *Blood*. 1979;54:928-32.
- Wilkinson JH. Lactate Dehydrogenase Isoenzymes. In *Isoenzymes*. New York: Springer. 1970, pp.134-203.
- Warburg O. On the origin of cancer cells. *Science*. 1956;123:309-14.
- Koppenol WH, Bounds PL, Dang CV. Otto Warburg's contributions to current concepts of cancer metabolism. *Nat Rev Cancer*. 2011;11:325-37.
- Ahuja P, Zhao P, Angelis E, et al. Myc controls transcriptional regulation of cardiac metabolism and mitochondrial biogenesis in response to pathological stress in mice. *J Clin Invest*. 2010;120:1494-505.
- Dang CV. c-Myc target genes involved in cell growth, apoptosis, and metabolism. *Mol Cell Biol*. 1999;19:1-11.
- Yun J, Rago C, Cheong I, et al. Glucose deprivation contributes to the development of KRAS pathway mutations in tumor cells. *Science*. 2009;325:1555-9.
- Ramanathan A, Wang C, Schreiber SL. Perturbational profiling of a cell-line model of tumorigenesis by using metabolic measurements. *Proc Natl Acad Sci USA*. 2005;102:5992-7.
- Elstrom RL, Bauer DE, Buzzai M, et al. Akt stimulates aerobic glycolysis in cancer cells. *Cancer Res* 2004;64:3892-9.
- Robey RB, Hay N. Is Akt the 'Warburg kinase'?-Akt-energy metabolism interactions and oncogenesis. *Semin Cancer Biol*. 2009;19:25-31.
- Deprez J, Vertommen D, Alessi DR, Hue L, Rider MH. Phosphorylation and activation of heart 6-phosphofructo-2-kinase by protein kinase B and other protein kinases of the insulin signaling cascades. *J Biol Chem*. 1997;272:17269-75.
- Matoba S, Kang JG, Patino WD, et al. p53 regulates mitochondrial respiration. *Science*. 2006;312:1650-3.
- Vousden KH, Ryan KM. p53 and metabolism. *Nat Rev Cancer*. 2009;9:691-700.
- Zhang C, Liu J, Liang Y, et al. Tumour-associated mutant p53 drives the Warburg effect. *Nat. Commun*. 2013;4:2935.
- Kruse O, Grunnet N, Barfod C. Blood lactate as a predictor for in-hospital mortality in patients admitted acutely to hospital: a systematic review. *Scand J Trauma Resusc Emerg Med*. 2001;19:74.
- Bloom BM, Grundlingh J, Bestwick JP, Harris T. The role of venous blood gas in the emergency department: a systematic review and meta-analysis. *Eur J Emerg Med*. 2014;21:81-8.

- 21. Rémiac F, Saint-Etienne C, Runge I, et al. Are central venous lactate and arterial lactate interchangeable? A human retrospective study. *Anesth Analg*. 2012;115:605–10.
- 22. Vitin AA, Azamfirei L, Tomescu D, Lang JD. Perioperative Management of Lactic Acidosis in End-Stage Liver Disease Patient. *J Crit Care Med (Targu Mures)*. 2017;3:55–62.
- 23. del Portal DA, Shofer F, Mikkelsen ME, et al. Emergency department lactate is associated with mortality in older adults admitted with and without infections. *Acad Emerg Med*. 2010;17:260–8.
- 24. Juneja D, Singh O, Dang R. Admission hyperlactatemia: causes, incidence, and impact on outcome of patients admitted in a general medical intensive care unit. *J Crit Care*. 2011;26:316–20.

Annex 1. A structured approach to hyperlactatemia and lactic acidosis

